


Two Males with SRY-Positive 46,XX Testicular Disorder of Sex Development

Sezgin Gunes, Ramazan Asci, Gülsen Okten, Fatih Atac, Onur E. Onat, Gonul Ogur, Oguz Aydin, Tayfun Ozcelik & Hasan Bagci


To cite this article: Sezgin Gunes, Ramazan Asci, Gülsen Okten, Fatih Atac, Onur E. Onat, Gonul Ogur, Oguz Aydin, Tayfun Ozcelik & Hasan Bagci (2013) Two Males with SRY-Positive 46,XX Testicular Disorder of Sex Development, *Systems Biology in Reproductive Medicine*, 59:1, 42-47, DOI: [10.3109/19396368.2012.731624](https://doi.org/10.3109/19396368.2012.731624)



To link to this article: <http://dx.doi.org/10.3109/19396368.2012.731624>

 View supplementary material 

 Published online: 30 Oct 2012.

 Submit your article to this journal 

 Article views: 307

 View related articles 

 Citing articles: 5 View citing articles 

CLINICAL CORNER: CASE REPORT

Two Males with SRY-Positive 46,XX Testicular Disorder of Sex Development

Sezgin Gunes^{1†*}, Ramazan Asci^{2†}, Gülsen Okten¹, Fatih Atac², Onur E. Onat³, Gonul Ogur⁴,
Oguz Aydin⁵, Tayfun Ozcelik³, and Hasan Bagci¹

¹Ondokuz Mayıs University, Faculty of Medicine, Department of Medical Biology, ²Ondokuz Mayıs University, Faculty of Medicine, Department of Urology, Samsun, Turkey, ³Bilkent University, Faculty of Science, Department of Molecular Biology and Genetics, Ankara, Turkey, ⁴Ondokuz Mayıs University, Faculty of Medicine, Department of Medical Genetics, Samsun, Turkey, ⁵Ondokuz Mayıs University, Faculty of Medicine, Department of Pathology, Samsun, Turkey

The 46,XX testicular disorder of sex development (46,XX testicular DSD) is a rare phenotype associated with disorder of the sex chromosomes. We describe the clinical, molecular, and cytogenetic findings of a 16- and a 30-year-old male patient with sex-determining region Y (SRY)-positive 46,XX testicular DSD. Chromosomal analysis revealed 46,XX karyotype. Fluorescence *in situ* hybridization (FISH) showed the SRY region translocated to the short arm of the X chromosome. The presence of the SRY gene was also confirmed by polymerase chain reaction (PCR). The X chromosome inactivation (XCI) assay showed that both patients have a random pattern of X chromosome inactivation. This report compares the symptoms and features of the SRY-positive 46,XX testicular DSD patients.

Keywords 46,XX Testicular DSD, mosaicism, SRY positive, XCI

Abbreviations 46,XX testicular DSD: 46,XX testicular disorder of sex development; SRY: sex-determining region Y; FISH: fluorescence *in situ* hybridization; PCR: polymerase chain reaction; XCI: X chromosome inactivation; PARs: pseudoautosomal regions; DXZ1: X centromere a-satellite probe.

Introduction

46,XX testicular disorder of sex development [46,XX testicular DSD; 46,XX gonadal dysgenesis; XX male syndrome (MIM 400045)] was described by De la Chapelle et al. in 1964 [De La Chapelle et al. 1964]. It is a rare disorder with an incidence of 1/20,000 males [De La Chapelle 1981]. Approximately 80% of the cases are sex-determining region Y (SRY)-positive, while the remaining cases are SRY-negative [Vilain 2003]. The presentation includes primary hypogonadism, small testes, gynecomastia, and hyalinization of seminiferous tubules, azoospermia, and

infertility [Ergun-Longmire et al. 2005]. In this study, we report the clinical, cytogenetical, fluorescence *in situ* hybridization (FISH), and molecular findings of two cases with SRY-positive 46,XX testicular DSD.

Clinical Report

Patient I

A 30-year-old male was referred from Urology Clinic with a five year history of male infertility. His wife had a healthy child from her first marriage. He has two healthy fertile brothers and one healthy sister. He presented a normal male phenotype with short stature, relatively poor beard, pubic and axillary hair development, gynecomastia, stretched penile length of 14 cm, small testes and normal intelligence (Table 1).

He was treated with human chorionic gonadotropin for six months and with clomiphene citrate in another clinic nine years ago. He had bilateral mastectomy eight years ago. Abdominal pelvic ultrasonography (USG) showed atrophic seminal vesicles and prostate and no mullerian derivatives.

Microscopic testicular sperm extraction (TESE) was performed. Testicular biopsies were taken from four different parts of the testes. After mechanical separation of seminiferous tubules, microscopic examination revealed no live or dead spermatozoa. Histopathological examination revealed an apparent thickening of the basal membrane and only Sertoli cells. There were no spermatogenic cells inside the lumen of seminiferous tubules. Extensively hyalinised seminiferous tubules were present, consistent with a Sertoli-cell-only syndrome (Fig. 1).

Patient II

Patient II was a 16-year-old male admitted to the Urology Clinic with complaints of having small testes and penis.

Received 21 April 2012; accepted 15 August 2012.

[†]These authors contributed equally.

*Address correspondence to Dr. Sezgin Gunes, Department of Medical Biology, Faculty of Medicine, Ondokuz Mayıs University, 55139, Samsun, Turkey. E-mail: sgunes@omu.edu.tr

Table 1. Clinical findings of patients.

	Patient I	Patient II
Age	30	16
Height (cm)	155	152
Body weight (kg)	70	65
Body mass index (kg/m ²)	27.3	22.5
Paternal consanguinity	Third degree	-
Secondary sexual characteristics	Marshall & Tanner stage 3	Marshall & Tanner stage 2
Age of pubertal onset	14	15
Clinical Features		
Bitesticular volume	4 cc on the left and 1 cc on the right	6 cc on the left and right
Palpable bilateral vas deferens	+	+
Gynecomastia	+ (Bilaterally operated)	-
Scrotum	Normal	Normal
Libido	Normal	Normal
Erection	Normal	Normal
Ejaculation volume	Low	Normal
Penile length (cm)	14	12.5
Abdominal Pelvic USG Data		
Prostate volume(cc)	10	Not investigated
Hormonal Profile		
Hypergonadotropic hypogonadism		
Endocrinological Data		
FSH (mU/mL)	37.88	41.05
LH (mIU/mL)	18.96	14.55
Prolactin (ng/mL)	17.54	24.11
TT (ng/mL)	0.510	2.16
	NR: 3.00-6.00 ng/mL	NR: 3.00-10.00 ng/mL
E ₂ (pg/mL)	17.57	32.00
Semen analysis	Azoospermia	Azoospermia
Pathological Findings		
	Sertoli-cell-only	Not investigated

NR: normal range

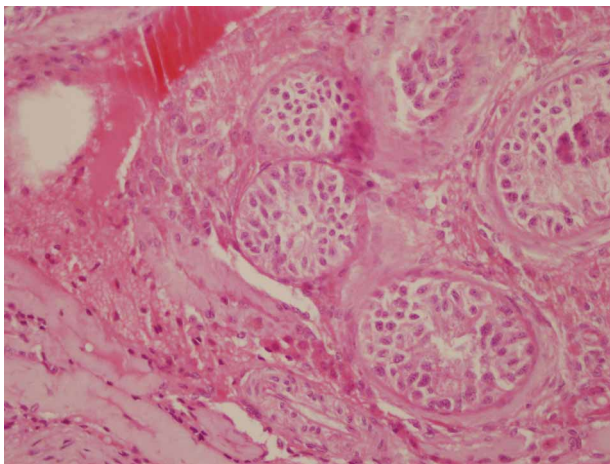


Figure 1. Histopathological results of testis biopsies of patient 1. Testicular histology shows an apparent decrease of seminiferous tubules in testicular parenchyma. Most of the seminiferous tubules show seminiferous tubule hyalinization and Sertoli-cells only syndrome with complete absence of spermatogenetic cells (Haematoxylin-eosin x400 magnification).

He was the second child of healthy parents. He has a 19 year old healthy brother. Past medical history was unremarkable with respect to probable risk factors such as trauma, medication, radiation, infection, or chemical exposure. He was born after a normal pregnancy period and delivery. His birth weight was 3,700 g and he reached puberty at the age of 15. At admission, his height was 152 cm (-3 SD). He

had a normal scrotum and a stretched penile length of 12.5 cm (Marshall & Tanner stage 2) [Marshall and Tanner 1970]. Testicular volume was 6 ml on the left and right and a vas deferens was palpable bilaterally. Testosterone replacement treatment with depot testosterone undecanoate was started due to hypogonadism. Table I presents the clinical findings of both patients.

Results and Discussion

Chromosomal analysis using GTG-banding revealed a 46,XX karyotype (450 bands of resolution) and both patients were diagnosed as XX males. PCR analysis showed amplification of sY1532, SRY, and ZFY genes that are located on the short arm of the Y chromosome (Fig. 2, Table 2). None of the tested AZFa, AZFb, and AZFc sequences could be detected. FISH analysis confirmed the presence of SRY translocated to the Xp region demonstrating a karyotype 46,XX. ish (DXZ1x1)[6]/(DXZ1x2,SRYx1)[243]/(DXZ1x3,SRYx2)[4] for patient I, and 46,XX.ish der(X)t(X;Y)(p22.3;p11.3)(SRY+) for patient II (Fig. 3, Table 2). Methylation analysis of the AR gene of both cases demonstrated random X chromosome inactivation (XCI) (53%:47% and 59%:41% skewing, respectively) in peripheral blood sample and 59% in testicular tissue in patient I (Fig. 4).

In this study, we describe the clinical, cytogenetic, and molecular features of two males with SRY-positive 46,XX testicular DSD. Both cases have the appearance of classical 46,XX, SRY positive male phenotypic features, namely,

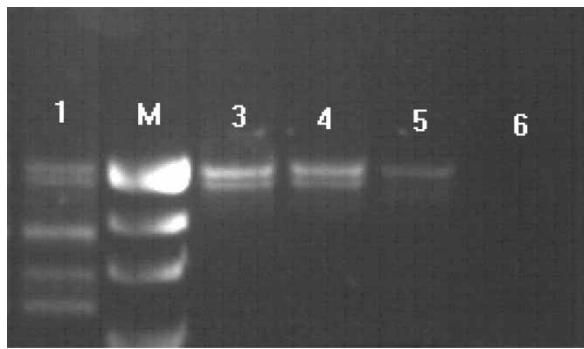


Figure 2. Electrophoresis of the PCR products of SRY+ chromosomes. Line 1, positive control (male); line 2, marker (R322DNA/BsuRI); line 3, SRY and ZFX/Y amplification of case I; line 4, SRY and ZFX/Y amplification of case II; line 5, female control; line 6, negative control.

azoospermia, decreased body height, and small testis. In comparison, some of 46,XX SRY-positive patients may present cryptorchidism or can have genital ambiguities and can even be true hermaphrodites. The variation of the phenotypic features of the SRY positive 46,XX males might be related with the length of the Y chromosomal material translocated on the short arm of the X chromosome [Bouayed Abdelmoula et al. 2003; Kusz et al. 1999], X inactivation pattern [Bouayed Abdelmoula et al. 2003; Kusz et al. 1999; Boucekkine et al. 1985; Schempp et al. 1989], position effect [Sharp et al. 2005] or presence of another Y linked gene [Bouayed Abdelmoula et al. 2003] which may have a role in male sexual development at the translocated segment.

Obligatory crossing over may take place between the X and Y chromosomes at the pseudoautosomal regions (PARs) during male meiosis. Along the non-recombining region of the Y chromosome, there are regions that have homology with the X chromosome but these regions do not normally undergo recombination [McElreavey and Cortes 2001]. The *SRY* gene encodes the 'testis-determining factor' which is essential for the development of the male during fetal life [Sinclair et al. 1990]. In some cases, a Y chromosome fragment can be translocated to the X chromosome by an aberrant interchange between the X and the Y chromosomes during paternal meiotic division [Ferguson-Smith 1966; Margarit et al. 2000]. The reason for this translocation could be the homology existing between the two

homologous genes, *PRKX* and *PRKY*. The sequence similarity between these genes is 94%. The *PRKY* gene is approximately 7 Mb away from the obligatory recombination region, PAR1 [Weil et al. 1994; Schiebel et al. 1997]. As a result of that recombination, the individuals have male sexual characteristics because of the presence of *SRY* gene on the X chromosome despite the XX sex chromosome pattern. The size of the translocated fragment is variable between SRY-positive XX males [Sharp et al. 2005; Vergnaud et al. 1986]. We did not determine in any of our cases the length of the translocated fragment.

The presence of the *SRY* gene on Xp leads to normal male sexual development. Though 46,XX testicular DSD patients usually have normal external genitalia, sometimes hypospadias or cryptorchidism may be seen [Yencilek and Baykal 2005]. Therefore, it is difficult to find 46,XX testicular DSD males before puberty. Our cases had no sexual ambiguities and were diagnosed after puberty [Wang et al. 2009]. Occasionally, SRY-positive XX males have sexual ambiguity despite having the *SRY* gene depending on the amount of material of Yp transferred to the X chromosome [Kusz et al. 1999; Queipo et al. 2002].

In 46,XX testicular DSD patients, the level of testosterone is normal during puberty but deficiency develops during adulthood leading to hypergonadotropic hypogonadism. In addition, infertility, and high levels of LH and FSH are observed [Yencilek and Baykal 2005]. In patient II, the testosterone level was mildly suppressed and a further decrease in the testosterone level is expected as presented in patient I. Microscopic examination of both testes showed hyalinization of most tubules in patient I without any spermatogenic cells, consistent with, Sertoli-cell-only syndrome [Bouayed Abdelmoula et al. 2003].

The XCI assay was used to determine whether preferential X-chromosome inactivation could be detected. Both patients showed a random inactivation pattern. The results of the XCI analysis in 46,XX testicular DSD patients are controversial [Bouayed Abdelmoula et al. 2003; Kusz et al. 1999; Boucekkine et al. 1985; Schempp et al. 1989; Vorona et al. 2007]. Both random and nonrandom X chromosome inactivation patterns have been reported. It has been suggested that there is no apparent relationship between phenotype and the pattern of X inactivation in SRY-positive 46,XX male patients. Additionally, the studied tissue can not fully represent all the tissues. According to our knowledge in most cases XCI analysis was performed on peripheral blood. XCI analysis was performed for both peripheral blood and testes for patient I to study tissue-specific patterns of X inactivation. Our results revealed that there is no preferential silencing of der(X;Y) in peripheral blood and testes. Differences in the size of the translocated fragment could lead to discrepancies of X chromosome inactivation analysis [Allen et al. 1992; Schempp et al. 1989; Queipo et al. 2002]. The length of the Y chromosome fragment in 46,XX male patients ranges from 40 kb to >75% of the Yp. The phenotypic differences could depend on the proximity of the breakpoint to the *SRY* gene. The presence or absence of cryptic

Table 2. Chromosomal and molecular analysis.

	Patient I	Patient II
Karyotype	46,XX	46,XX
sY1532, SRY and ZFY genes	+,+,+ (PB) and (T)	+,+,+ (PB)
AZF regions	-	-
Degree of skewness	%53 (PB), %59 (T)	%59 (PB)
FISH		
Patient I	46,XX. nuc ish(DXZ1x1)[6]/(DXZ1x2,SRYx1)[243]/(DXZ1x3,SRYx2)[4]	
Patient II	46,XX.ish der(X)t(X;Y)(p22.3;p11.3) (DXZ1x2)(SRY+)	

PB: peripheral blood, T: testis

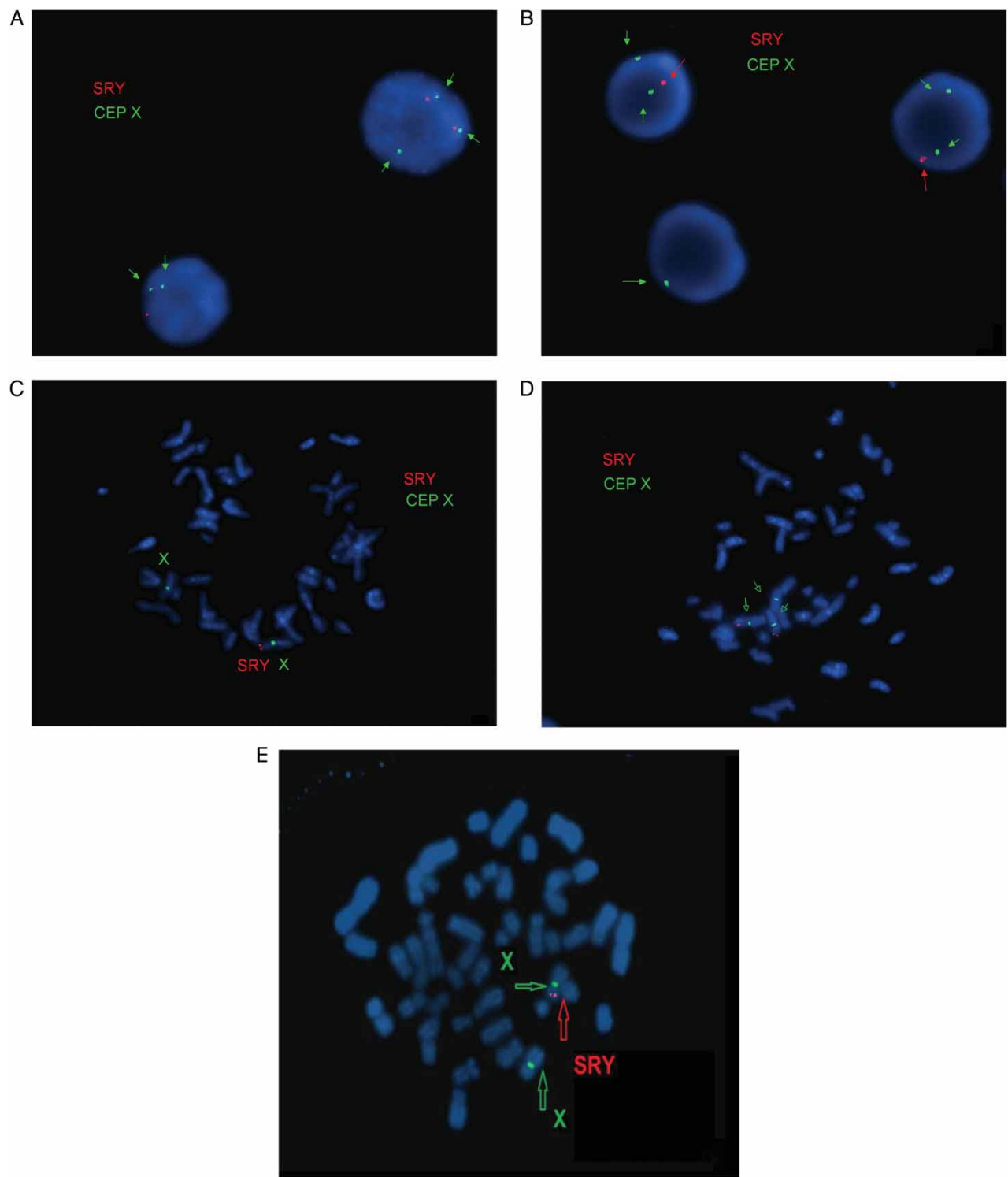


Figure 3. Fluorescence *in situ* hybridization (FISH) results. FISH analysis was performed on both interphase nuclei and metaphase spreads of patient I and on metaphase spreads of patient II. A-B) Interphase cells: A) 3 copies of DXZ1 and 1 copy of sex-determining region Y (SRY) (on top) and 2 copies of DXZ1 and 1 copy of SRY (on bottom); B) 2 copies of DXZ1 and 1 copy of SRY (on top) and only 1 copies of DXZ1 (on bottom); C-E) Metaphase cells: C) 2 copies of DXZ1 and 1 copy of SRY, D) 3 copies of DXZ1 and 1 copy of SRY, and E) 2 copies of DXZ1 and 1 copy of SRY (patient II). DXZ1:

recombinations may affect the expression of *SRY* gene by position effect [Sharp et al. 2005].

Recently Chernykh and colleagues [2009] reported X chromosomal mosaicism in a 37-year-old SRY positive 46,

XX male. Low grade mosaicism with three different cell lines was detected in patient I. It has been suggested that the presence of structurally normal and abnormal X chromosomes predisposes one to mitotic nondisjunction

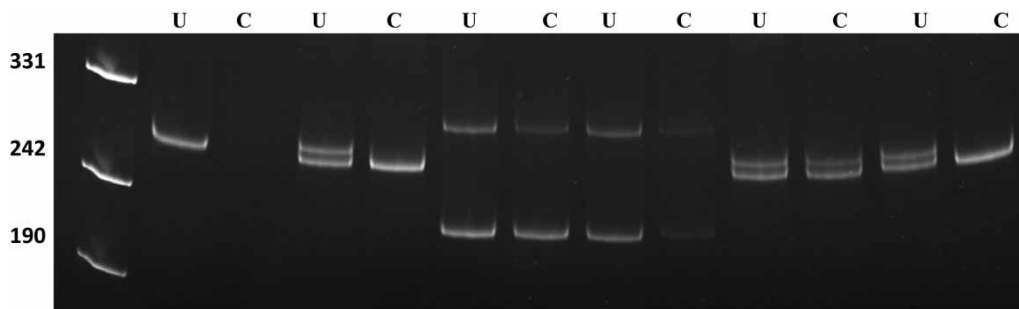


Figure 4. X chromosome inactivation pattern of case I and case II. PCR products of undigested (U) and *HpaII*-digested (C) DNA from peripheral blood and testis (Case I). XCI patterns of the cases. Line 1, marker (pUC mix 8), 331, 242 and 190 bp fragments are visible; line 2 and 3: male control; line 4 and 5, case I (PB); line 6 and 7, case I (T); 8 and 9 case II (PB); line 10 and 11, positive control. PB: Peripheral blood, T: Testis.

that can lead to X chromosomal mosaicism [Chernykh et al. 2009]. Abnormal mitotic segregation would be related with advanced age and cause X chromosomal mosaicism [Ogata et al. 2001] as it was in patient I.

In summary, we report two XX males with SRY gene at the end of the short arm of chromosome X. Both presented a classical phenotype and a normal XCI suggesting that skewed X inactivation is not mandatory for the distinct clinical signs of the disease.

Materials and Methods

Prior to the study, all patients were informed about the investigation and a signed consent form was obtained. All protocols involving the use of human tissue specimens were approved by the Institutional Review Board.

Cytogenetic analysis

Chromosomal analyses of peripheral blood samples were performed using standard procedures. Chromosome banding was achieved by Giemsa (GTG) method described in detail [Seabright 1971].

FISH analysis

FISH analysis was performed on both interphase nuclei and metaphase spreads of patient I and only on metaphase spreads of patient II (the supplement section contains details on FISH analysis of a third patient). FISH was performed on metaphase spreads and interphase nuclei of the lymphocytes, according to the manufacturer's instructions. X centromere (CEP X) and SRY-specific (LSI SRY) probes, (Vysis Inc., Downers Grove, IL, USA) were used.

Molecular analysis

The genomic DNA was isolated from peripheral venous blood samples of the patients by the 'salting out' method [Miller et al. 1988] and from testes using a commercially available kit (Invitrogen Genomic DNA Mini Kit, Carlsbad, CA, USA) according to the manufacturer's instructions. In addition to a negative control, normal male DNA and normal female DNA were used as controls. SRY (sY14 and sY1532), *ZFY*, sY84, sY86, sY127, sY134, sY254, sY255, *SMCY*, and *CDY2* locus amplification was performed using

multiplex PCR [Simoni et al. 2004; Nakashima et al. 2002]. The amplification products were resolved on 2% agarose and analyzed using a video gel documentation system (Biolabs, Kyoto, Japan) after staining with ethidium bromide.

X-chromosome inactivation analysis

DNA was isolated from blood sample of the patient using Nucleospin Blood kit (Macharey-Nagel, Düren, Germany) as in the protocol supplied by the manufacturer. X chromosome inactivation (XCI) pattern of the patient is determined by genotyping of the highly polymorphic CAG repeat in the androgen receptor (*AR*) gene, known as XCI assay, as in the protocol [Ozbalkan et al. 2005; Allen et al. 1992]. Briefly, DNA was digested with methylation specific restriction enzyme *HpaII* (MBI Fermentas, Vilnius, Lithuania), which cleaves unmethylated (or active) X fragments. Therefore, the methylated (or inactive) X chromosome remains intact for PCR amplification. PCR products were separated on 8% denaturing 29:1 acrylamide:bisacrylamide gel for 4 h at constant 15W. MultiAnalyst version 1.1 software (Bio-Rad, Hercules, California) was used for densitometric analysis of the alleles.

Testicular histology

Testicular biopsy was taken during microscopic TESE under spinal anesthesia in the operating room. The specimen fixed in Bouin's solution was delivered to the pathology laboratory. Following the fixation, routine procedure was performed and sections were stained with Haematoxylin-eosin (H&E) [Magid et al. 1990].

Declaration of interest: The authors report no conflict of interest.

Author contributions: Preparation of the manuscript, molecular and cytogenetic analysis: SG; Preparation of the manuscript, clinical evaluation of the patients: RA; Director of Cytogenetics Laboratory: GO; Preparation of testis biopsy and histological evaluation: OA; Preparation of some parts of the manuscript, clinical evaluation of the patients: FA; XCA and preparation of related parts in manuscript: OEO; FISH analysis and editing of manuscript: GO; XCA and editing of manuscript: TO; Editing of manuscript: HB.

Note of added Proof

The X chromosome inactivation (XCI) assay of a third patient showed a non-random pattern of X chromosome inactivation (Supplemental Fig. 1 – 4 and Supplemental Tables I and II). As detailed in the Supplement we report three XX males with *SRY* gene at the end of the short arm of chromosome X. All patients presented a classical phenotype with normal and completely skewed XCI suggesting that skewed X inactivation is not mandatory for the distinct clinical signs of the disease.

References

- Allen, R.C., Zoghbi, H.Y., Moseley, A.B., Rosenblatt, H.M. and Belmont, J.W. (1992) Methylation of HpaII and HhaI sites near the polymorphic CAG repeat in the human androgen-receptor gene correlates with X chromosome inactivation. *Am J Hum Genet* **51**:1229-1239.
- Bouayed Abdelmoula, N., Portnoi, M.F., Keskes, L., Recan, D., Bahloul, A., Boudawara, T., et al. (2003) Skewed X-chromosome inactivation pattern in SRY positive XX maleness: a case report and review of literature. *Ann Genet* **46**:11-18.
- Boucekkine, C., Nafa, D., Casanova-Bettane, M., Latron, F., Fellous, M. and Benmiloud, M. (1985) Evidence of a preferential inactivation of the paternally derived X chromosome in a 46,XX true hermaphrodite. *Hum Genet* **69**:91-93.
- Chernykh, V.B., Kurilo, L.F., Shilova, N.V., Zolotukhina, T.V., Ryzhkova, O.P., Bliznetz, E.A., et al. (2009) Hidden X chromosomal mosaicism in a 46,XX male. *Sex Dev* **3**(4):p183-187.
- De La Chapelle, A., Hortling, H., Niemi, M. and Wennström J (1964) XX sex chromosomes in a human male. First case. *Acta Med Scand* **412**:25-38.
- De La Chapelle, A. (1981) The etiology of maleness in XX men. *Hum Genet* **58**:105-116.
- Ergun-Longmire, B., Vinci, G., Alonso, L., Matthew, S., Tansil, S., Lin-Su, K., et al. (2005) Clinical, hormonal and cytogenetic evaluation of 46,XX males and review of the literature. *J Pediatr Endocrinol Metab* **18**:739-748.
- Ferguson-Smith, M.A. (1966) X-Y chromosomal interchange in the aetiology of true hermaphroditism and of XX Klinefelter's syndrome. *Lancet* **288**:475-476.
- Kusz, K., Kotecki, M., Wojda, A., Szarras-Czapnyk, M., Latos-Bielenska, A., Warenik-Szymankiewicz, A., et al. (1999) Incomplete masculinisation of XX subjects carrying the SRY gene on an inactive X chromosome. *J Med Genet* **36**:452-456.
- Magid, M.S., Cash, K.L. and Goldstein, M. (1990) The testicular biopsy in the evaluation of infertility. *Semin Urol* **8**(1): p51-64.
- Margarit, E., Coll, M.D., Oliva, R., Gomez, D., Soler, A. and Ballesta, F. (2000) SRY gene transferred to the long arm of the X chromosome in a Y-positive XX true hermaphrodite. *Am J Med Genet* **90**:25-28.
- Marshall, W.A. and Tanner, J.M. (1970) Variations in the pattern of pubertal changes in boys. *Arch Dis Child* **45**:13-23.
- McElreavey, K. and Cortes, L.S. (2001) X-Y translocations and sex differentiation. *Semin Reprod Med* **19**:133-139.
- Miller, S.A., Dykes, D.D. and Polesky, H.F. (1988) A simple salting out for extracting DNA from human nucleated cells. *Nucleic Acids Res* **16**:1215.
- Nakashima, M., Koh, E., Namiki, M. and Yoshida, A. (2002) Multiplex sequence-tagged site PCR for efficient screening of microdeletions in Y chromosome in infertile males with azoospermia or severe oligozoospermia. *Arch Androl* **48**(5):p351-351.
- Ogata, T., Matsuo, M., Muroya, K., Koyama, Y. and Fukutani, K. (2001) 47,XXX male: A clinical and molecular study. *Am J Med Genet* **98**(4):p353-353.
- Ozbalkan, Z., Bagislar, S., Kiraz, S., Akyerli, B., Ozer, H.T., Yavuz, S., et al. (2005) Skewed X chromosome inactivation in blood cells of women with scleroderma. *Arthritis Rheum* **52**:1564-1570.
- Queipo, G., Zenteno, J.C., Peña, R., Nieto, K., Radillo, A., Dorantes, L. M., et al. (2002) Molecular analysis in true hermaphroditism: demonstration of low-level hidden mosaicism for Y-derived sequences in 46,XX cases. *Hum Genet* **111**:278-283.
- Schempp, W., Müller, G., Scherer, G., Bohlander, S.K., Rommerskirch, W., Fraccaro, M., et al. (1989) Localization of Y chromosome sequences and X chromosomal replication studies in XX males. *Hum Genet* **81**:144-148.
- Schiebel, K., Winkelmann, M., Mertz, A., Xu, X., Page, D.C., Weil, D., et al. (1997) Abnormal XY interchange between a novel isolated protein kinase gene, PRKY, and its homologue, PRKX, accounts for one third of all (Y+) XX males and (Y-) XY females. *Hum Mol Genet* **6**:1985-1989.
- Seabright, M. (1971) A rapid banding technique for human chromosomes. *Lancet* **2**:971-972.
- Sharp, A., Kusz, K., Jaruzelska, J., Tapper, W., Szarras-Czapnik, M., Wolski, J., et al. (2005) Variability of sexual phenotype in 46,XX (SRY+) patients: the influence of spreading X inactivation versus position effects. *J Med Genet* **42**:420-427.
- Simoni, M., Bakker, E. and Krausz, C. (2004) EAA/EMQN best practice guidelines for molecular diagnosis of y-chromosomal microdeletions. State of the art 2004. *Int J Androl* **27**(4):p240-240.
- Sinclair, A.H., Berta, P., Palmer, M.S., Hawkyns, J.R., Griffiths, B.L., Smith, M.J., et al. (1990) A gene from the human sex-determining region encodes a protein with homology to a conserved DNA-binding motif. *Nature* **346**:240-244.
- Vergnaud, G., Page, D.C., Simmler, M.C., Brown, L., Rouyer, F., Noel, B., et al. (1986) A deletion map of the human Y chromosome based on DNA hybridization. *Am J Hum Genet* **38**:109-124.
- Vilain, E.J. (2003) 46,XX Testicular Disorder of Sex Development. In: GeneReviews [Internet]. Pagon, R.A., Bird, T.C., Dolan, C. R., Stephens, K., ed. Seattle, (WA): University of Washington, Seattle.
- Vorona, E., Zitzmann, M., Gromoll, J., Schüring, A.N. and Nieschlag, E. (2007) Clinical, endocrinological, and epigenetic features of the 46,XX male syndrome, compared with 47,XXY Klinefelter patients. *Clin Endocrinol Metab* **92**:3458-3465.
- Wang, T., Liu, J.H., Yang, J., Chen, J. and Ye, Z.Q. (2009) 46, XX male sex reversal syndrome: a case report and review of the genetic basis. *Andrologia* **41**:59-62.
- Weil, D., Wang, I., Dietrich, A., Poustka, A., Weissenbach, J. and Petit, C. (1994) Highly homologous loci on the X and Y chromosomes are hot-spots for ectopic recombinations leading to XX maleness. *Nat Genet* **7**:414-419.
- Yencilek, F. and Baykal, C. (2005) 46,XX male syndrome: a case report. *Clin Exp Obst Gyn* **32**:263-264.

Notice of Correction

The version of this article published online ahead of print on 30 Oct 2012 contained errors in order of the figures and supplemental figures, additionally two figures had been missed. These errors have been corrected for this version.